

The Value of Dual-Source Computed Tomography of the Chest in the Surgical Planning of Repeated Cardiac Surgery

Konstantin Nikolaou¹, Ferdinand Vogt², Calin Vicol², Tobias Saam¹, Jens Müller-Starck¹, Maximilian F. Reiser¹, Christoph R. Becker¹, Carsten Rist¹

Purpose: When reoperative cardiac surgery is indicated, detailed, three-dimensional imaging of the thorax is mandatory to depict cardiac anatomy and vascular structures to increase the safety of the surgical procedure. We sought to evaluate the contribution of dual-source multidetector-row computed tomography (DSCT) of the heart and thorax in the planning of repeated open heart surgery.

Materials and Methods:

- 28 patients (mean age 68 years) scheduled for repeated cardiac surgery underwent contrast-enhanced ECG-gated DSCT
- 19 had previous coronary artery bypass grafting
- 8 underwent cardiac valve replacement
- 1 had a combined valvular and bypass surgery

Indication for repeated surgery:

Bypass surgery (n=6), valve replacements (16), combined bypass and valvular surgery (5) or other reasons (1). Surgical risk was assessed from the following DSCT data:

- relation of the ascending aorta and cardiac structures
- graft patency and anatomic course
- degree of calcification of the ascending aorta and the coronary arteries

Results:

Influence of DSCT on surgical approach:

- 15 surgical approaches (54%) remained unchanged
- 13 were changed:
 - in 9 patients (32%), the surgical approach was changed (3 cases, non-midline incision; 5 cases, surgery performed under circulatory arrest; 1 case, femoral arterial cannulation before sternotomy)
 - in 4 patients, surgery was cancelled (in 2 cases heavy aortic and coronary calcifications impeded bypass surgery; 2 cases showed right heart or aortic aneurysm in close proximity to the sternum)

DSCT demonstrated 54 bypass graft conduits (20 arterial, 34 venous) in 21 patients after earlier bypass grafting. Of these 54 grafts, 16 arterial grafts and 24 vein grafts were patent, whereas 4 arterial grafts and 10 venous grafts were occluded.

Conclusion:

DSCT of the heart and thorax is a promising, non-invasive tool for the preoperative planning of repeated cardiac surgery and can provide significant information to modify the surgical approach and increase the safety of the procedure.

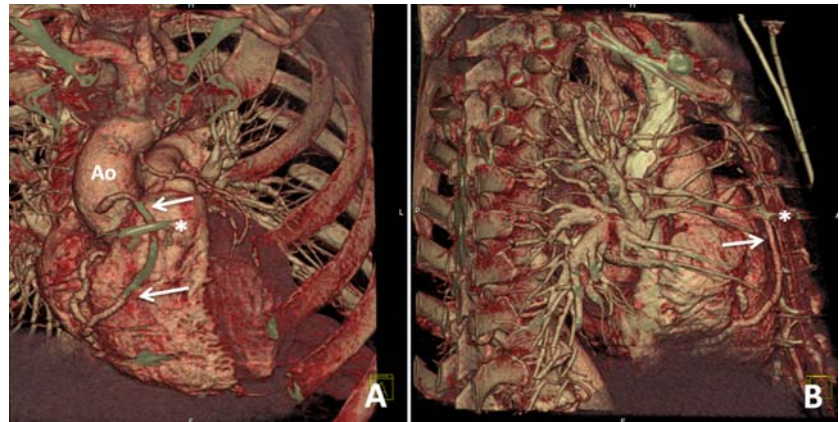


Figure 1

Volume rendered reconstruction (VRT) of a 51-year old man with previous coronary artery bypass grafting (Figure 1A coronal view, Figure 1B sagittal view). Planned for mitral valve repair. The saphenous vein graft to the right coronary artery (arrow) and its close proximity to the sternal wire (*). Ao=ascending aorta

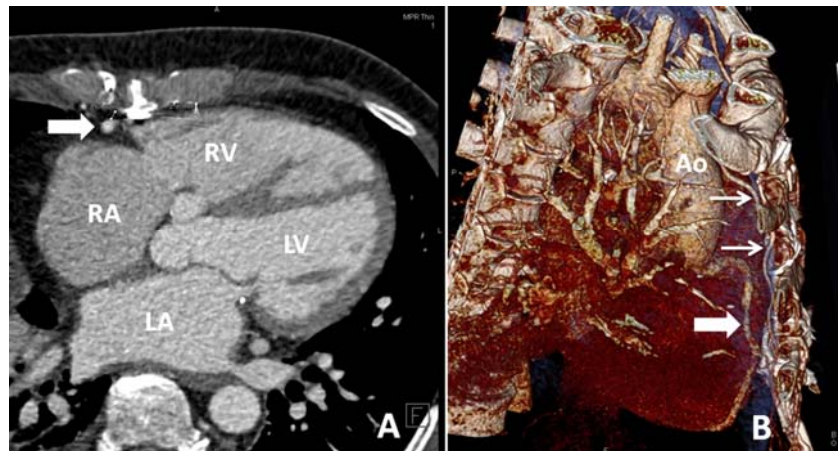


Figure 2

Axial image of a DSCT dataset of a 59-year old man with previous bypass grafting. Example of a high-risk finding, with right coronary artery (arrowhead) in very close distance (3 mm) to the sternum (A). Note also the proximity of a left internal mammary artery (LIMA) bypass graft (arrow) to the sternum, as shown in the volume-rendered image (VRT) (B) Ao=Aorta, L=left ventricle, RV=right ventricle, LA=left atrium, RA=right atrium.)

All CT's were done by Somatom Definition, Siemens Medical Solutions of the whole thorax with a temporal resolution of 82 ms and a spatial resolution of 0.4 mm³